Heart Embryology at a Glance

Weeks	Days	Cardiac Events
1-2	0-20	No heart or great vessels
3	20	Cardiogenic plate
3	21	Endocardial tubes
4	22	Fusion of endocardial tubes
4	23	Single median cardiac tube, first contraction (ineffective)
4	25	Cardiogenic loop
4	26	Single atrium
5	29	Bi-lobed atrium
5	30	Beginning of circulation
5	31	Septum primum
5	35	A-V orifice, 3 chamber heart
6	36	Septum secundum
6	39	Complete inferior septum
6	40	Septation of bulbus and ventricle
6	42	Divided truncus arteriosus
7	49	4-chambered heart, Absorption of pulmonary veins

Scanned with CamScanner

Early Heart Tube Differentiation

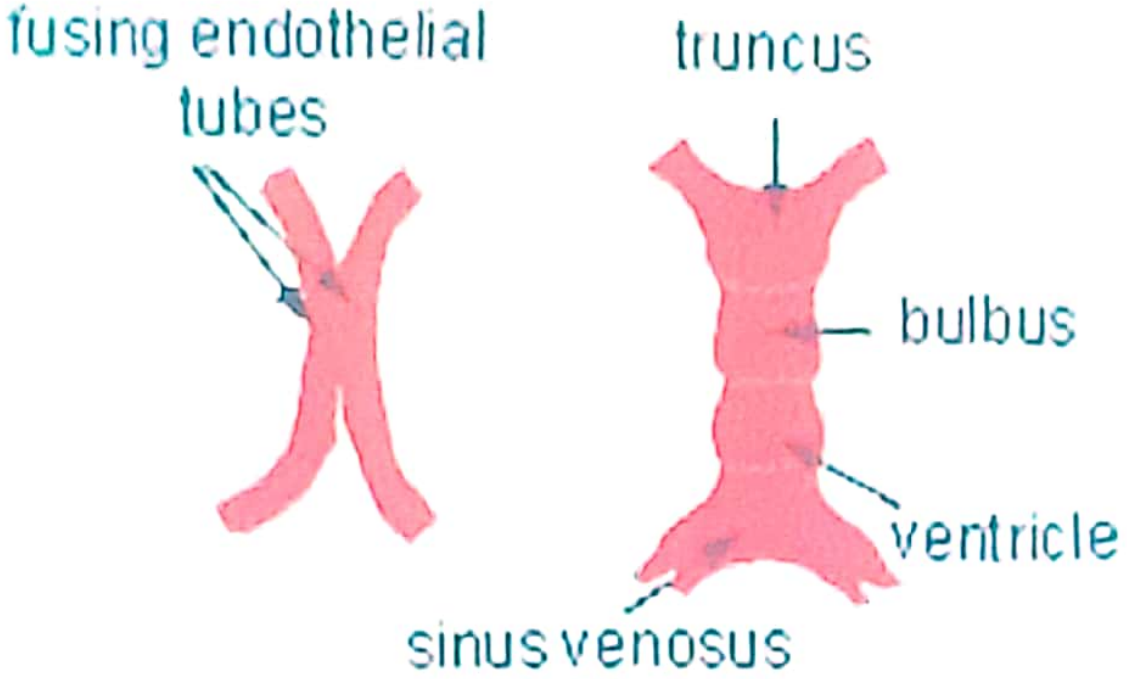

Scanned with CamScanner

CHD: Pathophysiology

- Left to right shunts
  - Oxygenated blood recirculates in lungs
- Right to left shunts
  - Desaturated blood bypasses lungs
- Transposition
  - Circulations in parallel
- Obstruction
  - Increased workload on cardiac chamber

Scanned with CamScanner

Atrial Septal Defects

1. Patent foramen ovale
2. Secundum ASD
3. Primum ASD
4. Sinus Venosus ASD
5. Coronary Sinus ASD
6. Common atrium

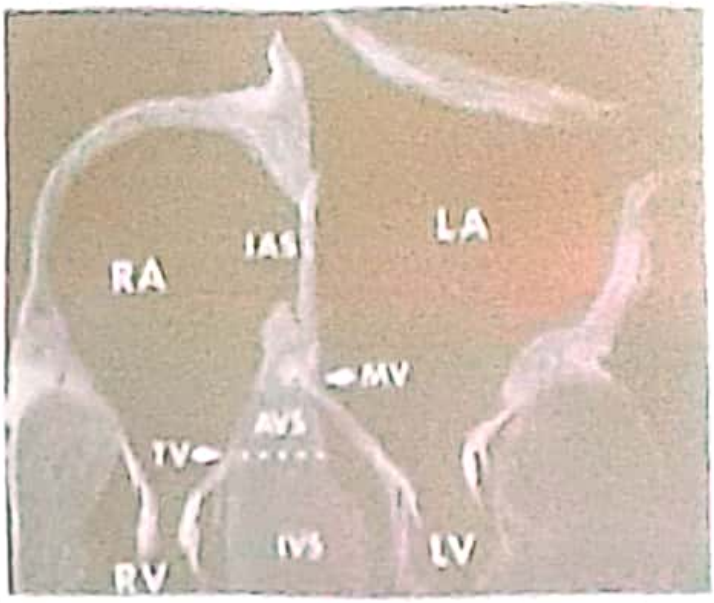

Scanned with CamScanner

ASD - Clinical Findings

- Usually asymptomatic
- Fixed widely split S2
- Systolic Ejection murmur at LUSB, radiates to lung fields
- Soft diastolic murmur at LLSB
- Precordial bulge and RV heave
- Prolonged P-R interval and IRBBB

Scanned with CamScanner

Natural history and complications

- Spontaneous closure
  - Diameter<3-5mm
- Patent
  - Arrhythmia –atrial Fib
  - Heart failure
  - Pulmonary hypertension
  - Paradoxical emboli
  - Mitral valve prolapse

Scanned with CamScanner

ASD treatment

- Surgical closure
- By device in the cath-lab

Scanned with CamScanner

Ventricular Septal Defect

Scanned with CamScanner

VSD Physiology

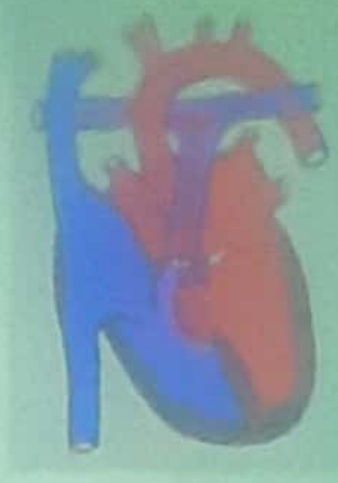

- Physiology is determined by size of VSD
- Small to medium size defects are pressure limiting or "restrictive"
- Large defects provide no resistance to flow between the ventricles - "non-restrictive"
- In large VSDs the flow across the defect is determined by the relative resistance in pulmonary and systemic vascular beds
- Patients with large VSD have pulmonary arterial hypertension
  - If low PVR, lots of flow, lots of symptoms
  - If high PVR, less flow, may be asymptomatic

Press = Flow x Resist

Scanned with CamScanner

Clinical picture VSD

- Congestive heart failure
- Symptoms
  - Sweat during feeds
  - Difficulty in feeding
  - Inadequate weight gain

- 2-3 weeks
  - Tachypnea
  - Tachycardia
  - Mottled skin
  - Cold periphery
  - Enlarged liver

Scanned with CamScanner

VSD COURSE

- Congestive heart failure
- Pulmonary hypertension
- Large VSD but balanced heart failure
- Spontaneous closure
- Develop RV outflow obstruction
- Aortic insufficiency
- Endocarditis

Scanned with CamScanner

VSD - management

- Unrepaired VSDs do NOT need SBE prophylaxis
  - Practice good oral hygiene!
- Symptomatic defects - medical first
  - Diuretics, ACEI, nutrition, time
  - Perimembranous and muscular defects may have spontaneous closure
- Indications for interventions:
  - Failure of medical management
  - Aortic insufficiency
  - Qp/Qs > 2:1, volume load in older children
  - Pulmonary Hypertension - repair before 1 year of age
- Eisenmenger's - inoperable

Scanned with CamScanner

VSD - management

- Unrepaired VSDs do NOT need SBE prophylaxis
  - Practice good oral hygiene!
- Symptomatic defects - medical first
  - Diuretics, ACEI, nutrition, time
  - Perimembranous and muscular defects may have spontaneous closure
- Indications for interventions:
  - Failure of medical management
  - Aortic insufficiency
  - Qp/Qs > 2:1, volume load in older children
  - Pulmonary Hypertension - repair before 1 year of age
- Eisenmenger's - inoperable

Scanned with CamScanner

VSD definitive management

- Catheterization
  - device closure
- Surgery
  - closure

Scanned with CamScanner

Ventricular Septal Defect

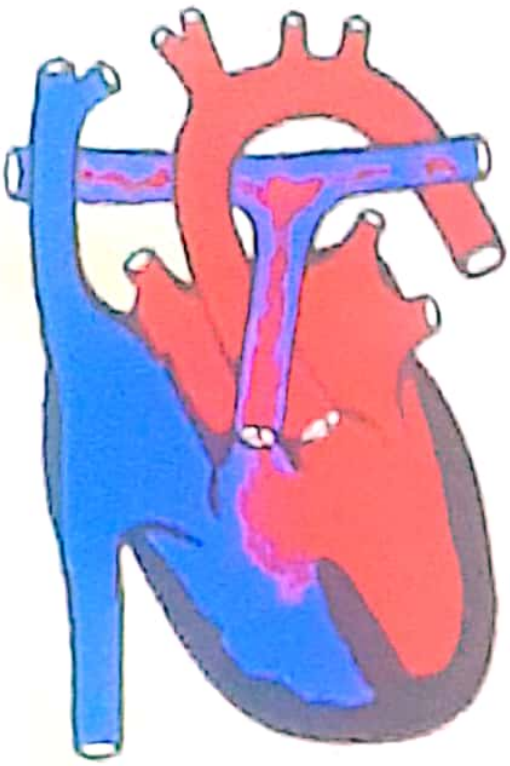

VSD before surgical repair

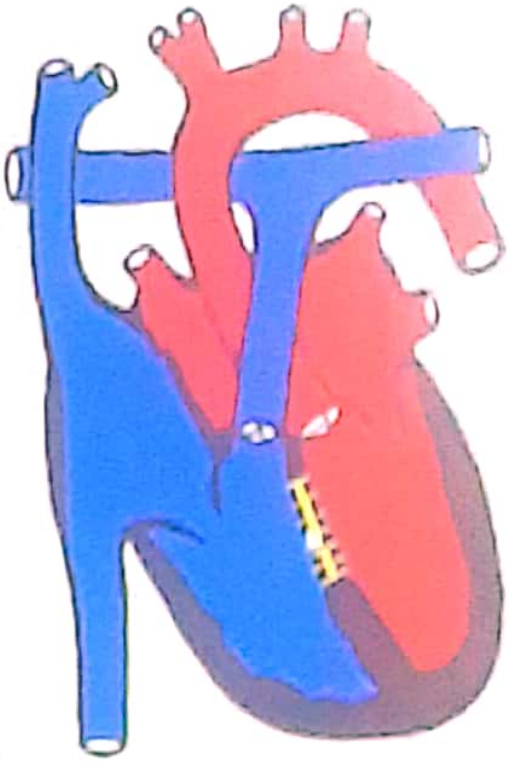

VSD after surgical repair

Scanned with CamScanner

COARCTATION OF THE AORTA

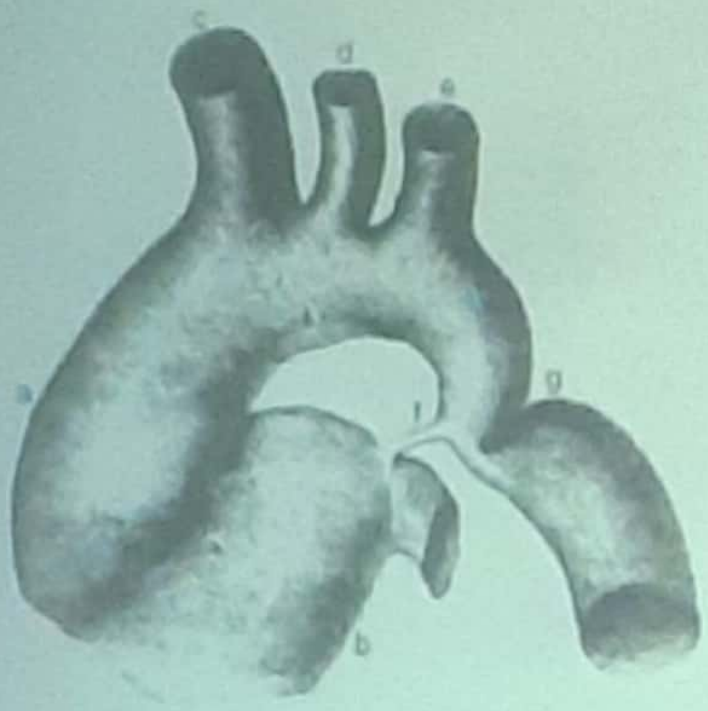

- Congenital narrowing of the aorta
  - Most typically at the isthmus
- Discrete shelf or longer segment narrowing

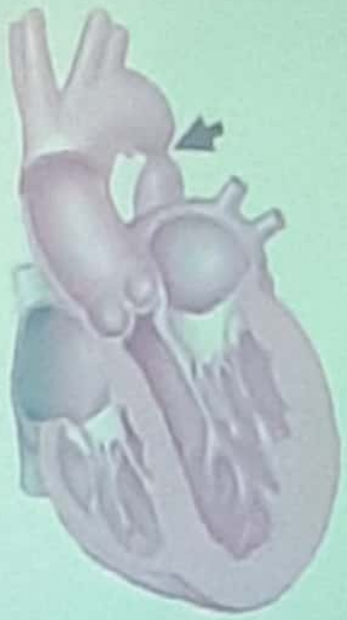

Scanned with CamScanner

Coarctation – associated lesions

- 85% have associated Bicuspid Ao Valve
- "Simple coarctation"
  - In older patients, usually
  - In infants, half are "simple"
- "Complex coarctation" – associated with other intra-cardiac lesions
  - VSD
  - Valvular/sub-valvular Ao Stenosis
  - Shone's complex
  - TGA with VSD
  - ASD
  - Single ventricle

Scanned with CamScanner

Collaterals often develop

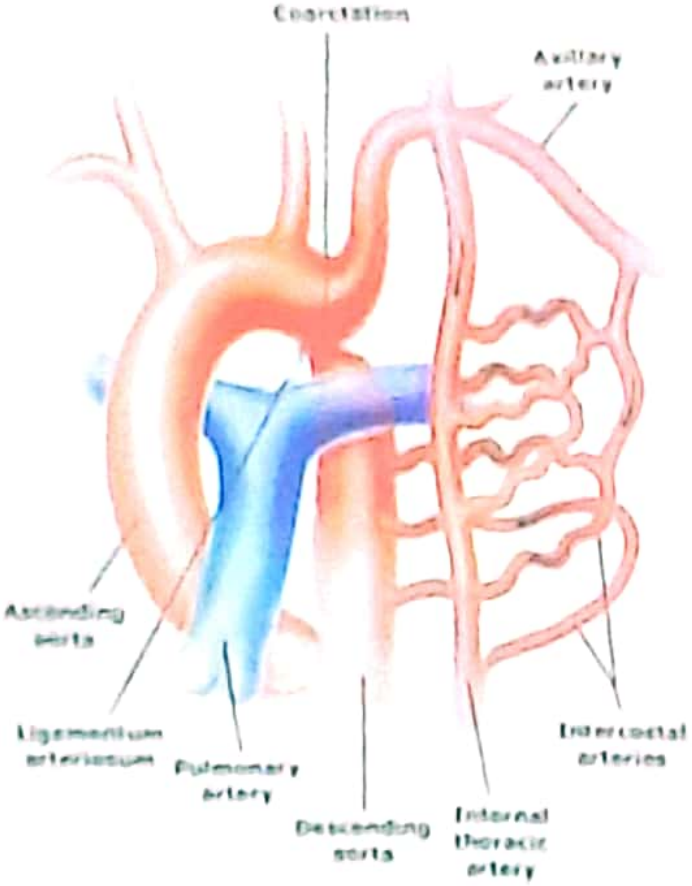

Scanned with CamScanner

Coarctation late presentation

- Late presentation (older child or adult)
  - Referred for murmur, high BP or Turner's
  - Asymptomatic (rarely headache or claudication)
  - Decreased, delayed pulses in lower extremities
  - 3-4% have anomalous R subclavian artery (ARSA)
    - Arises distal to coarctation so remember to check pulses in all 4 extremities
    - Compare right and left
  - Systolic BP difference in upper and lower extreme
    - measure supine with correct cuff size
  - Gradient may be mild (<20 mmHg) or severe (as high as 80 mmHg)

Scanned with CamScanner

Presentation in older child/adult - continued

- Prominent impulse at apex
- Thrill
- Normal S1 and S2, ejection click (if BAV)
- 2-3/6 SEM at LUSB radiates to Left scapula
- Continuous murmurs throughout chest from collaterals
- Systolic BP difference in upper and lower extremities (measure supine with correct cuff size)

Scanned with CamScanner

Treatment

- **Surgery** – various techniques
  - For all newborns
  - Some older patients
  - Requires cross clamping aorta with risk of spinal ischemia
  - Risk increases if poorly developed collateral circulation
- **Primary balloon angioplasty**
  - Procedure of choice for re-stenosis after surgery
  - For selected children with discrete shelf - controversial
  - Risk of dissection, late aneurysm formation
  - Considered palliative only in small neonates
- **Percutaneous stent**
  - For fully grown patients
  - Reduces risk of aneurysm
  - Suitable for long segment stenosis

Scanned with CamScanner

Endovascular stent for coarctation

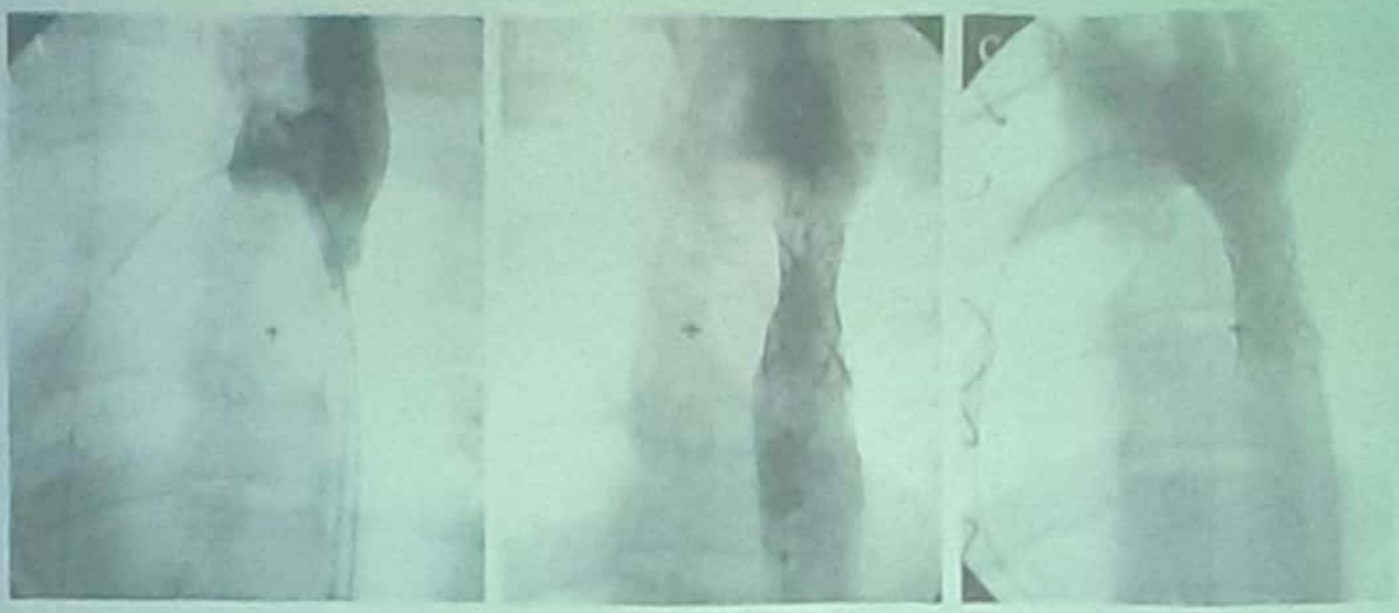

Figure 1. Descending aorta angiogram in the frontal projection in a 26-year-old female patient (weight = 77 kg) with severe coarctation of the aorta with a peak gradient of 75 mmHg. (A) Angiogram using a Multisnare catheter demonstrating tight coarctation (arrow) with a diameter < 1.5 mm. (B) Repeat angiogram after deployment of a 24 mm Cheatham Platinum stent mounted over a BIB catheter (maximum balloon diameter 9 mm) and over balloon diameter of 12 mm), demonstrating a good result (arrow). (C) Final angiogram after further expansion with a 16 mm ZOOM balloon (maximum balloon expansion) the stent at a diameter of 14 mm and a gradient reduction to zero.

Serially expanded up to 14 mm diameter with reduction in gradient to zero

Scanned with CamScanner

Patent Ductus Arteriosus
(Friend or Foe?)

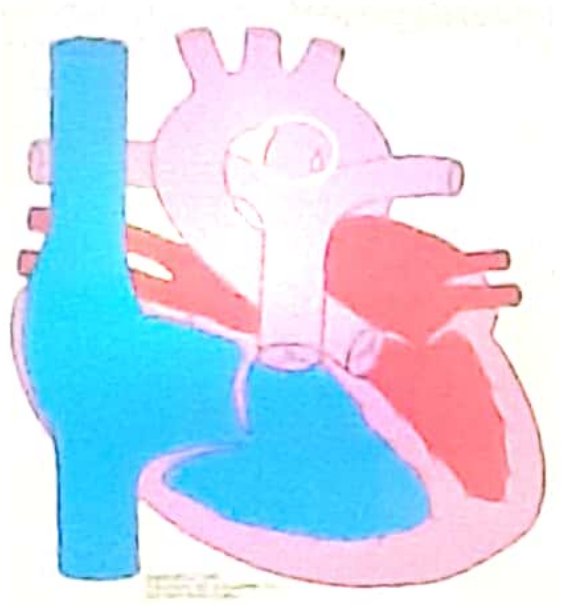

Magnitude of shunt depends on

1. Pressure gradient
   - Ao and PA
2. Resistance within PDA

Scanned with CamScanner

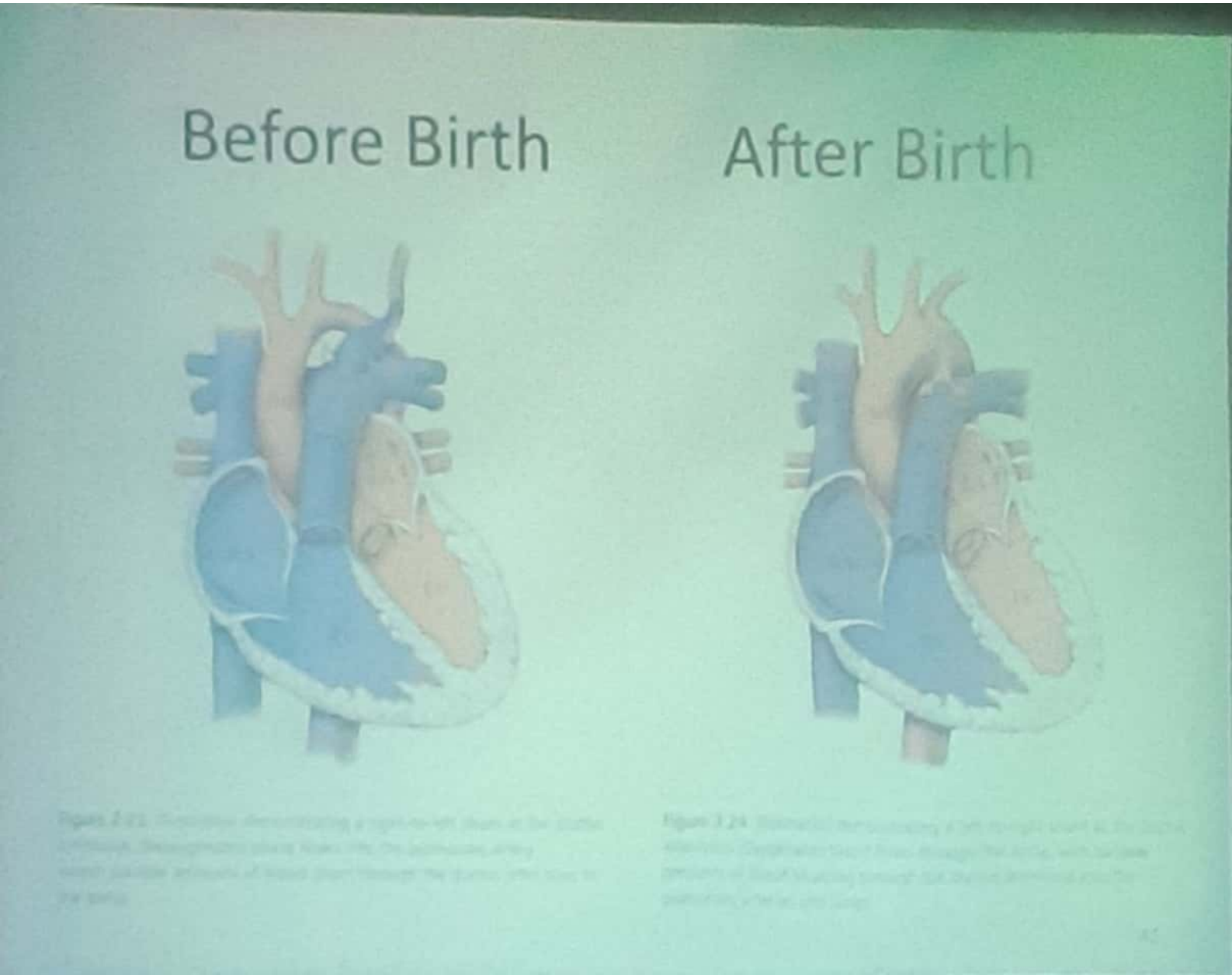

Scanned with CamScanner

PDA pathophysiology

- Pulmonary over-circulation
- Decreased lung compliance (increased WOB)
- Increased pulmonary venous return to LA
- Left heart enlargement
- Diastolic run-off in aorta with low diastolic BP
- Eventual pulmonary vascular disease (Eisenmenger's)
- May present with murmur, CHF, A. fib, endocarditis, or as an incidental finding
- Rarely there is an aneurysm of the ductus which may rupture or impinge on recurrent laryngeal nerve

Scanned with CamScanner

PDA Treatment

- Medical management of Heart failure
  - diuretics, afterload reduction, nutrition
- Surgical Ligation (standard or thoracoscopic)
  - symptomatic infants
  - older patients who are not candidates for transcatheter based therapy
- Catheterization
  - Coil occlusion,
  - Amplatzer device
  - Other devices
- Pulm vasodilators for pts with Eisenmenger's

Scanned with CamScanner

When the ductus is your friend

Scanned with CamScanner

Ductal Dependent Lesions

(In CHD)

- Right heart obstruction
  - Need PDA for pulmonary blood flow
    - Critical PS, TOF, PA, TA
- Left heart obstruction
  - Need PDA for systemic blood flow
    - Critical AS, CoArc, HLHS, IAA
- PDA needed for mixing
  - dTGA

Scanned with CamScanner

Atrioventricular Canal Development

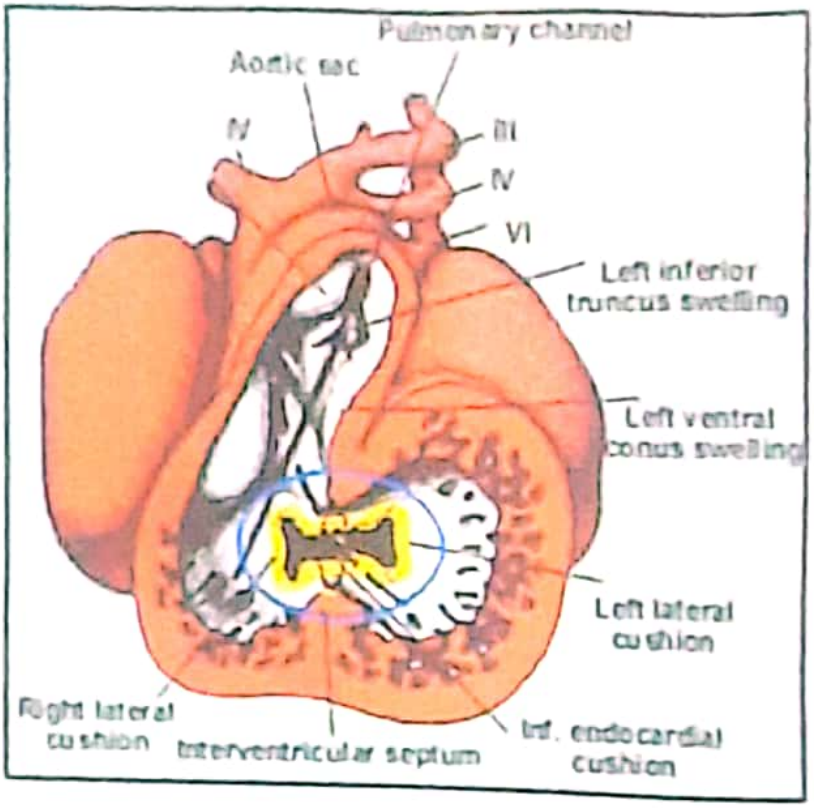

Scanned with CamScanner

Complete AV Canal

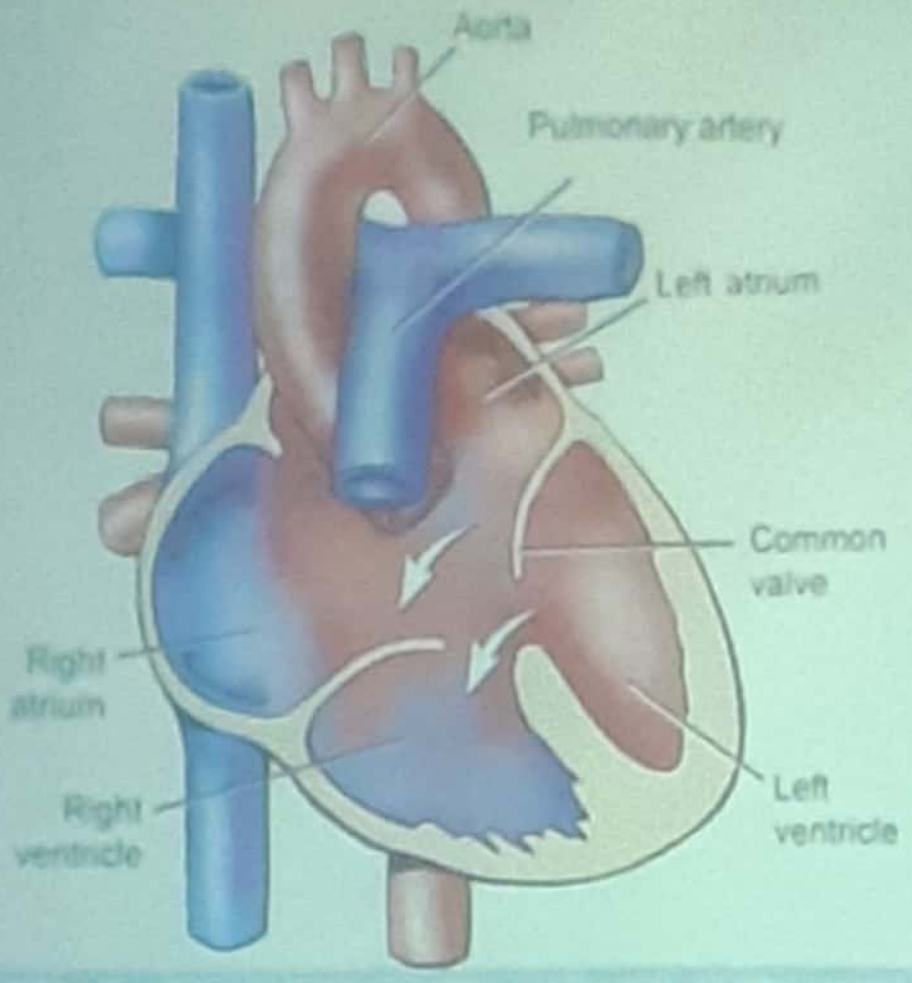

Associated with:
1. Trisomy 21

Scanned with CamScanner

Valve Stenosis

Anatomy

Obstructive physiology

- Numerous levels of obstruction
  - » Valve (90%)
  - » Subvalve
  - » Supravalve

Scanned with CamScanner

Cyanotic Heart diseases

Scanned with CamScanner

Intracardiac Rt. To Lt. shunting

- Parallel circulations
  - Transposition of the great vessels
- Reduced pulmonary blood flow
  - Tetralogy of Fallot
  - Pulmonary Atresia
- Complete mixing normal or increased pulmonary blood flow
  - Single ventricle

Scanned with CamScanner

Tetralogy of Fallot

- 1.VSD
  - large, unrestrictive
  - malalignment type
- 2. Overriding Aorta
- 3. Pulmonary Stenosis
  - infundibular
  - valvular
  - hypoplasia of PAs
- 4. RVH

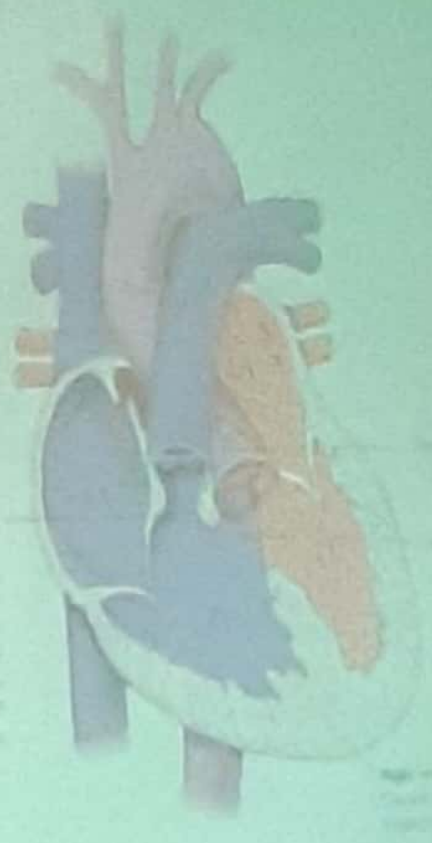

Anterior deviation of the infundibular septum

Scanned with CamScanner

Physiology

- VSD is non-restrictive
- direction and magnitude of shunt depends on severity of RVOT obstruction
  - Severe RVOTO: more R to L shunt
  - Mild RVOT: less R to L shunt
- RVOT obstruction may be dynamic
- "Pink Tet" if RVOT obstruction is minimal, net L to R shunt, behave like a large VSD

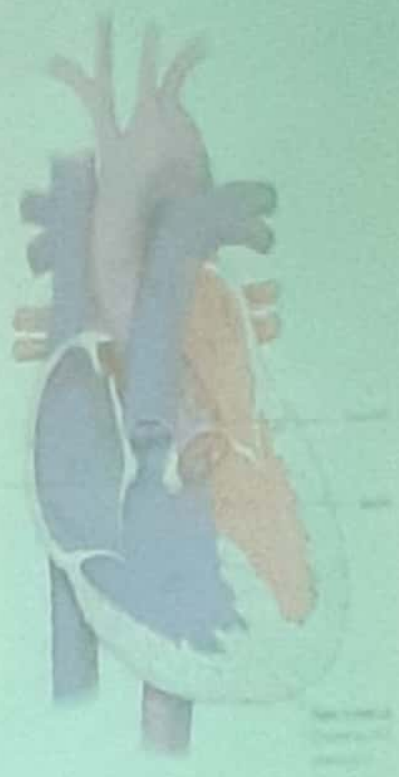

Scanned with CamScanner

Clinical Presentation

- Newborn presents with murmur or cyanosis
- O_2 Sat gradually declines over time
- Hypercyanotic Spells
  - acute onset of intense cyanosis with hyperpnea due to spasm of the infundibulum
  - Decreased PBF, severe hypoxemia, altered level of consciousness, very high mortality
  - Rx: Calm, O_2, knee chest, phenylepherine, surgery, b-blocker
- ECG - RVH, RAD (RBBB after repair)
- S&S: Squatting, clubbing (unrepaired), cyanosis

Scanned with CamScanner

CXR in TOF

- heart size small or normal
- upturned apex
- concave LUSB
- "boot shaped"
- Right Aortic Arch – 25%
- normal or decreased vascular markings

Scanned with CamScanner

Tetralogy of Fallot

"Tet Spells"

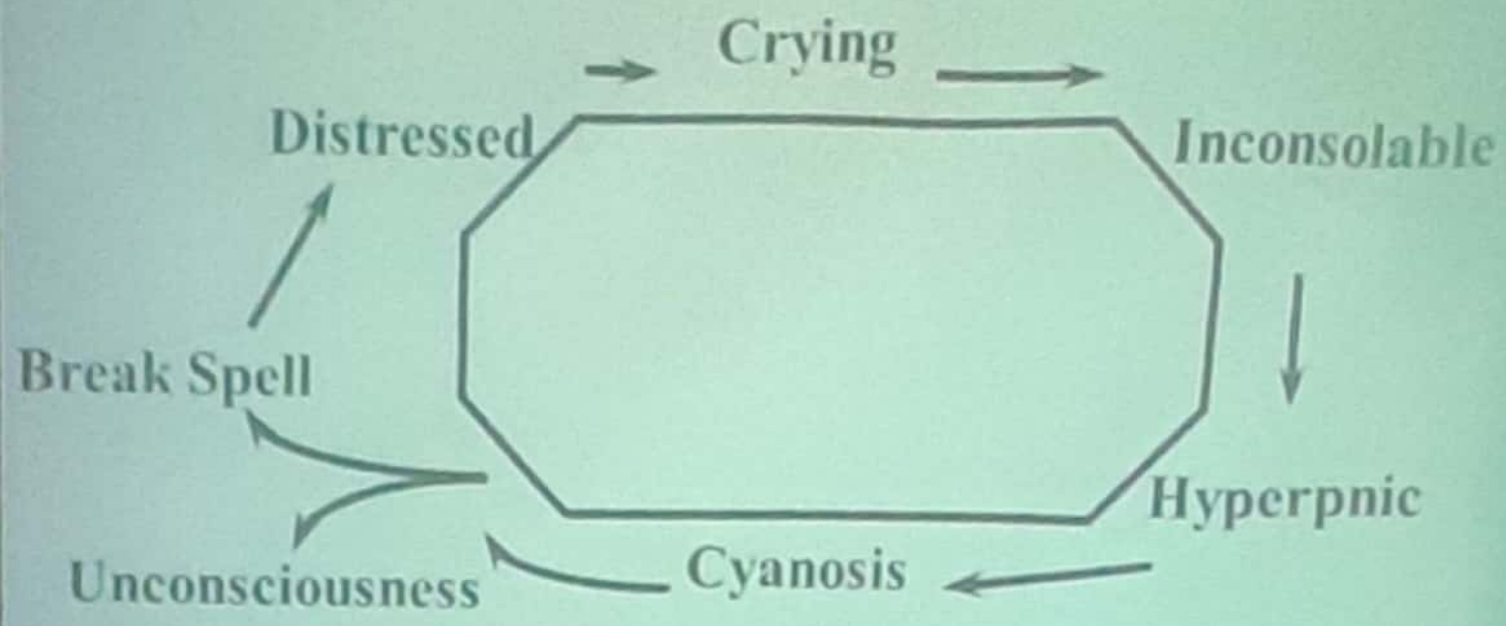

Scanned with CamScanner

Tetralogy of Fallot

"Tet Spells"

Treatment

- Avoid agitation
- Knee chest
- Volume
- Sedation (morphine/ketamine)
- Propranolol
- Phenelyepherine
- Emergency surgery

Scanned with CamScanner

Transposition of the Great Vessels

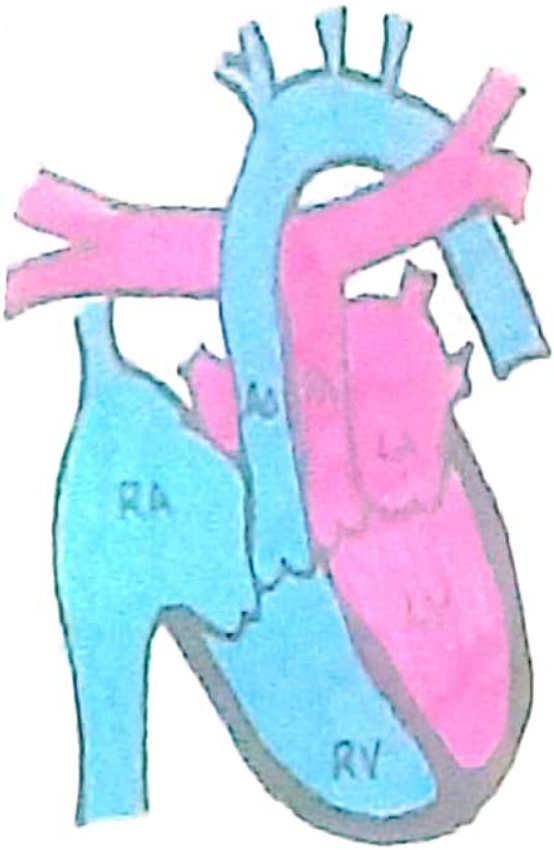

- Normal "dextro" looping of ventricles abnormal rotation of the great arteries
- Atrio-ventricular concordance with ventriculo-arterial discordance
  - Pulmonary arises from left ventricle
  - Aorta arises from right ventricle
- Simple dTGA
- Complex dTGA – associated lesions
  - VSD
  - ASD
  - PDA
  - Valve stenosis
  - Coronary anomalies frequent

Scanned with CamScanner

Transposition of the Great Vessels

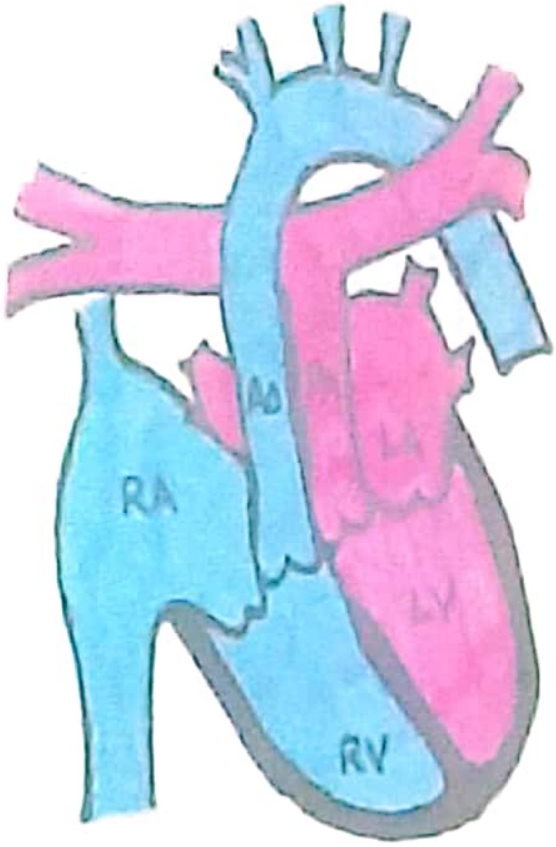

- Normal "dextro" looping of ventricles abnormal rotation of the great arteries
- Atrio-ventricular concordance with ventriculo-arterial discordance
  - Pulmonary arises from left ventricle
  - Aorta arises from right ventricle
- Simple dTGA
- Complex dTGA – associated lesions
  - VSD
  - ASD
  - PDA
  - Valve stenosis
  - Coronary anomalies frequent

Scanned with CamScanner

TGA Presents at birth with severe cyanosis

Mixing occurs at ASD/PFO, PDA and VSD, if present

blood mixing through
ASD & PDA

Immediate stabilization:

1. Start PGE1 (since the 1980's)
2. Balloon Atrial Septostomy

Scanned with CamScanner

Truncus Arteriosus

Scanned with CamScanner

Truncus Arteriosus

Anatomy

Left to right shunt

- Single arterial trunk supplies pulmonary and systemic circulation
- Ventricular septal defect

Scanned with CamScanner

Univentricular Hearts
"single ventricles"

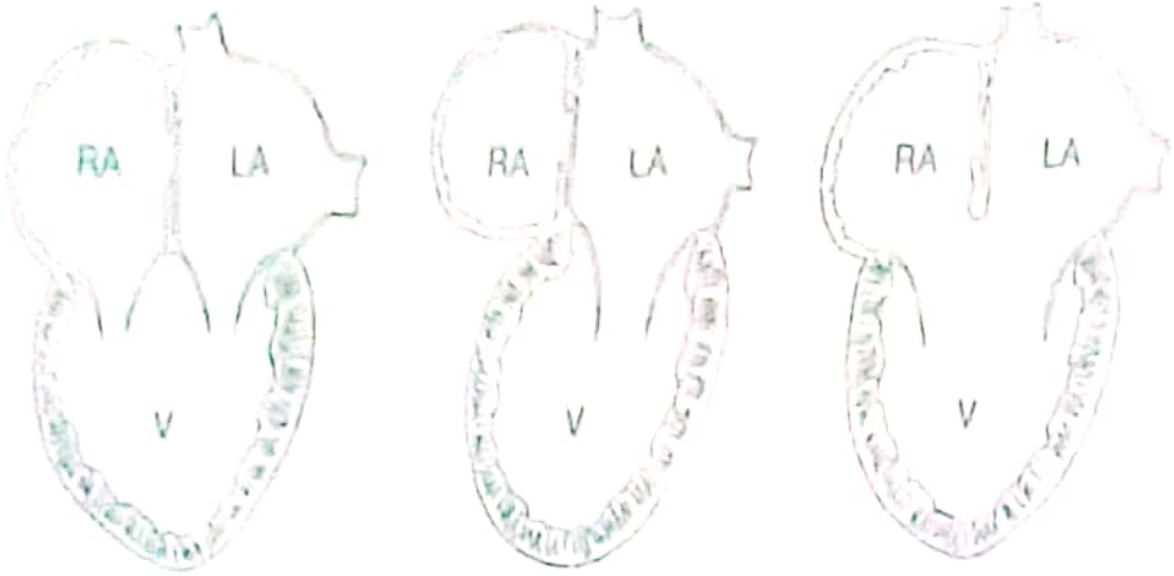

Double inlet (univentricular)

Single inlet (univentricular)

Common inlet (univentricular)

Scanned with CamScanner

Univentricular Hearts
"single ventricles"

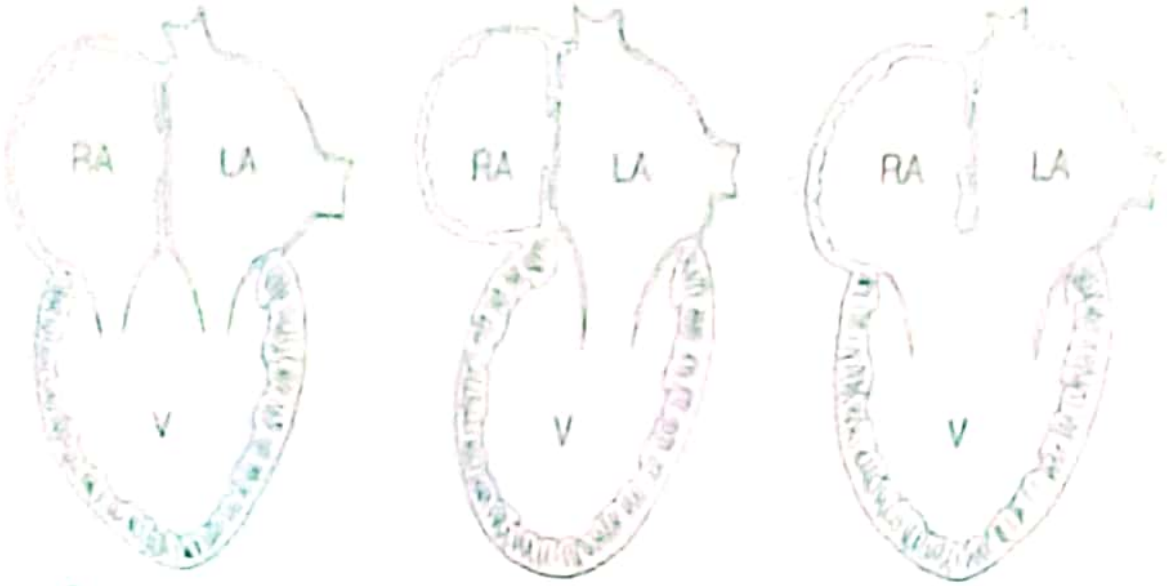

Double inlet (univentricular)

Single inlet (univentricular)

Common inlet (univentricular)

Scanned with CamScanner

Tricuspid Atresia

Hypoplastic left heart

Scanned with CamScanner

Pulmonary Venous Anomalies

- Total Anomalous pulmonary venous Connections (TAPVC)
  - Failure of normal connection between pulmonary venous plexus AND CPV before splanchnic venous system have regressed.
  - Type I: Supracardiac (47%)
  - Type II: Cardiac (16%)
  - Type III: Infradiaphragmatic (13-23%)
  - Type IV: Mixed((7-10%)

Scanned with CamScanner

Supra Cardiac
TAPVC

Infra Cardiac
TAPVC

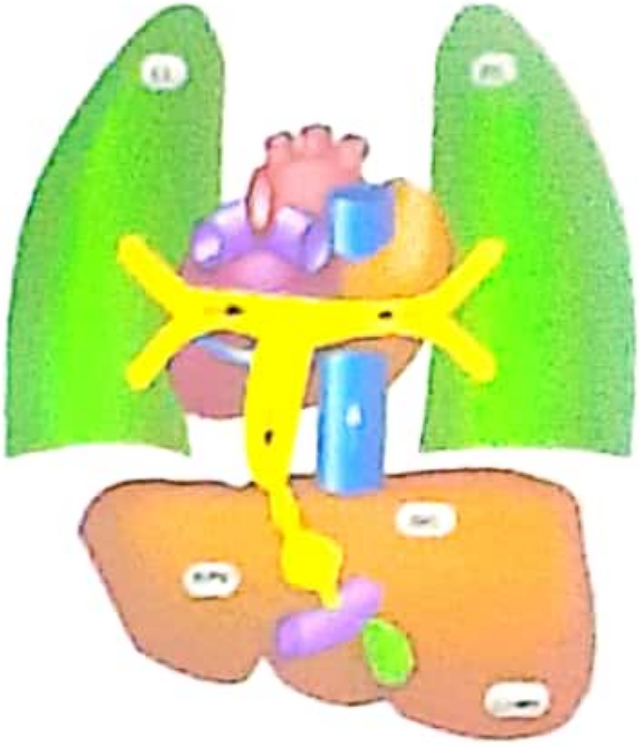

Scanned with CamScanner